

Report for the APSS Depuy-Synthes Spine Clinical Fellowship 2015

Fellow : Young-Tae, Kim

Clinical instructor (Orthopaedics,Spine), Inha University Hospital, Incheon, Korea

Guide : Zhuojing Luo,

Professor of Fourth Military Medical University, Xi'an, China

Director of Orthopaedic department, Xijing Hospital, Xi'an, China

Duration : 18 May ~ 3 June 2015

Visited Center : Orthopaedic Department of Xijing Hospital

Prologue

To be honest, I did not know well about APSS and APSS fellowship program before the APSS Myanmar Operative Spine Course.

I joined APSS Myanmar Operative Spine Course which be held on 6th - 8th February 2015. I met Professor Ki-Tack, Kim who was Chairman of Korean Spine Society Association. He gave me the information about APSS fellowship. After returned to Korea, I looked for the APSS fellowship program and applied the fellowship program. I remembered that I was so happy at the day I received the acceptance letter from APSS committee. I appreciated Professor Kim to give me a chance to joint this program.



Professor Kim and me in the Myanmar.

I attached to Professor Zhuojing Luo who was a chief of orthopaedics department of Xi-jing hospital in China. This is my first visit to China.

I arrived on 17th May via direct flight from Incheon and check in Sangri-la Hotel which place just around the Xi-jing hospital.

My fellowship program consisted of attending outpatient clinic, spine conference and operation. My fellowship had started from 18th May.

Programme

Day	Time	Programme
Monday	8:00-12:00, 15:00-17:00	Outpatient Day
Tuesday	9:00-17:00	Operation Day
Wednesday	8:00-12:00	Spine Conference – Case Presentation
Thursday	8:00-12:00, 15:00-17:00	Outpatient Day
Friday	9:00-17:00	Operation Day
Saturday	-	Free & Easy
Sunday	-	Free & Easy

My fellowship program.

Week 1 (18th May - 22th May)

At first day, I'm very surprised that there are too many people in the street and hospital. After I experienced countless people, I met many great orthopaedic surgeons at Xi-jing hospital.




Too many people in the hospital.



36 great orthopaedic surgeons at Xi-jing hospital.

18th May (Mon)

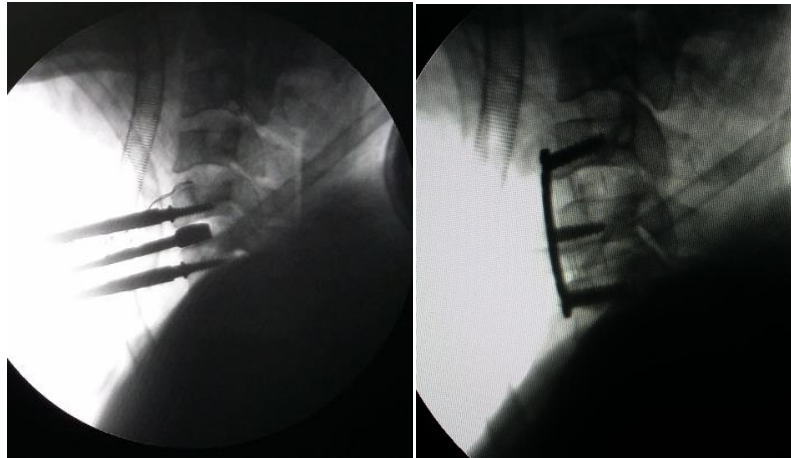
I attended the outpatient clinic of Pf. Luo. The case of outpatient clinic includes the cervical and lumbar degenerative disease and trauma. Especially, the patients who were operated by other hospital surgeon wanted to meet to Pf. Luo for the secondary opinion. Pf. Luo was kind to patient and gave them the advice. Patients almost came in the outpatient clinic with unhappy face. After they met to Pf. Luo, they always left the clinic with happy face.



Pf. Luo and me in the outpatient clinic

19th May (Tue)

My first operation case in Xi-jing hospital was a 51 year old male. He had complaint of posterior neck pain and radiating pain to left arm. Pf. Wang who was a colleague of Pf. Luo, performed the ACDF at C45,C56 level. He was very delicate and careful. He checked the proper implant size using intra-operative radiograph. The operation was successful. The second was a ruptured huge herniated disc at L45 level and wide decompression with traditional TLIF was performed. The third case was a spinal stenosis and traditional TLIF was done.



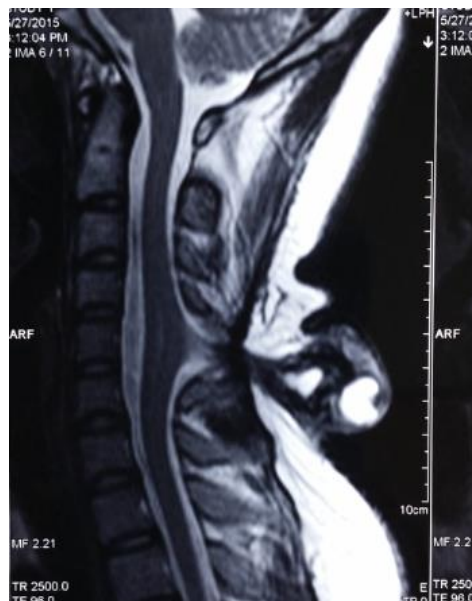
The 2 level cervical disc treated with ACDF.

20th May (Wed)

This day was the special day. The Chinese officials investigated the Xi-Jing hospital. They checked the quality of operation room and instrumentation. Thus, I did not attend spine conference.

21th May (Thu)

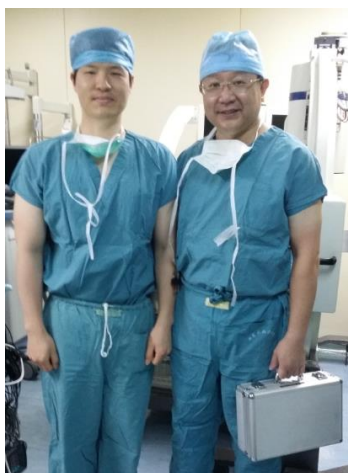Today I attended the outpatient clinic of Pf. Wang. There were some interesting cases. The patient was my mostly impressive case in outpatient clinic. She had complaint of mass like lesion on the posterior neck area. Her MRI showed the cervical myelomeningocele. It was the first time that I see. We recommended the neurosurgery clinic after discussing about this case.



The cervical myelomeningocele case.

22th May (Fri)

Today I attended the Pf. Luo operation. There were 2 surgeries. The first case was 68 year old female, suffering from spinal stenosis and both leg radiating pain. She had many medical disease including the asthma and heart problem. We could not take the MRI because the radiology department refuse her to take MRI due to the high risk. Pf. Luo decided to perform the decompression only surgery. Pf. Luo finished the whole operation within 1 hour. His surgery was prompt and correct. The second case was traditional spinal stenosis. Pf. Luo performed the wide decompression and TLIF.



Pf. Luo and me in the operation room

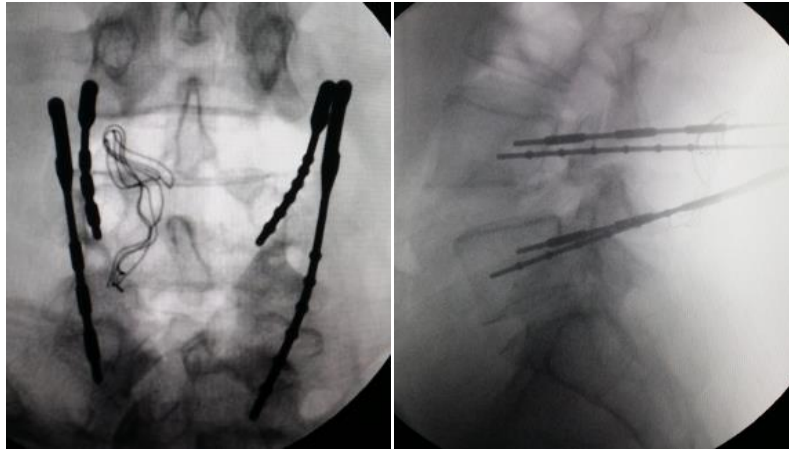
Week 2 (25th May - 29th May)

25th May (Mon)

I attended the outpatient clinic of Pf. Wang. About 20 patients visited his clinic. The patients consisted of degenerative cervical and lumbar disease.

26th May (Tue)

There were 3 surgeries. The first case was a 48 year old female with spondylolytic spondylolisthesis at L45. Pf. Wang performed decompression and TLIF as he usually did. He used special device to find exact pathway of pedicle screw. Some markers were on the special device. This markers represented the depth and the direction of pedicle screw. The second case was recurrent herniated disc at L45. Pf. Wang preformed the laminectomy and discectomy. The last case was huge disc herniation at L5S1. Pf. Wang performed the decompression and traditional TLIF.



The special device that helps to find exact pathway of pedicle screw

27th May (Wed)

This day was for spine conference. During the conference, we reviewed the operated cases and discussed in some difficult cases. Especially, they invited the patient and they performed physical examination and discussed to solve the problem of the patient. It was very impressive to me.



The spine conference with the real patient

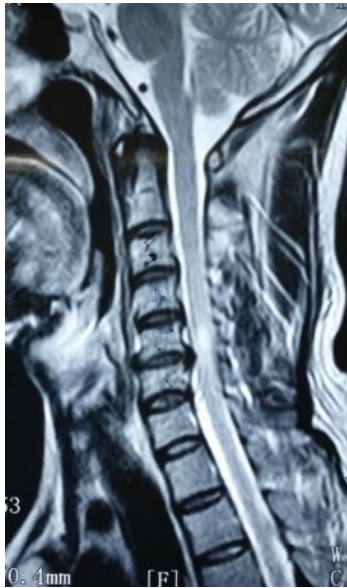
28th May (Thu)

Thursday was the outpatient clinic day.

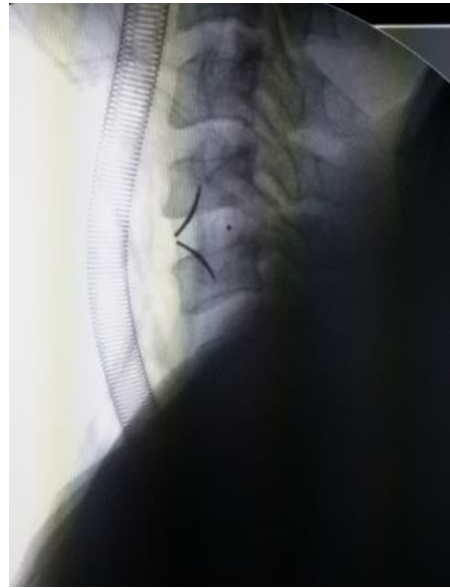29th May (Fri)

Pf. Wang had two operations today. The first case was a 58 year old female patient with spinal stenosis over L45. He performed the decompression and TLIF. The second case was a 50 year old male patient with cervical myelopathy due to the herniated disc at C56. Pf. Wang performed the

delicate anterior decompression until he reached anterior dural surface. After the perfect decompression, he inserted the stand alone cage which was added the blade



Herniated disc at C56



Stand alone cage with blade

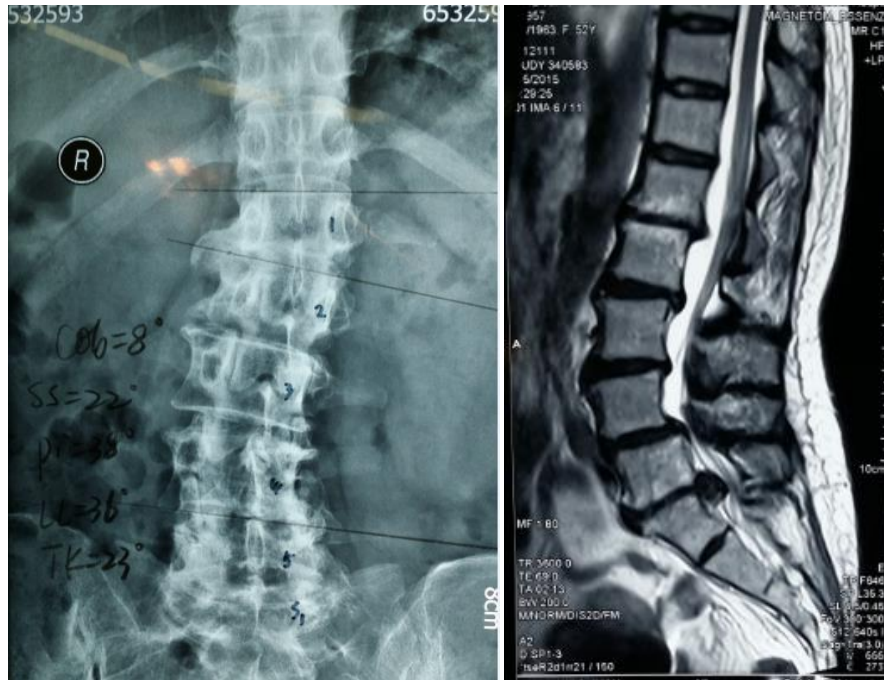
Week 3 (1st June - 3rd June)

1st June (Mon)

Every Monday and Thursday was the outpatient clinic day.

2nd June (Tue)

There were 2 operation cases. The first case was spinal stenosis at L4/5 level. The treatment of this case was traditional TLIF. The second case was a difficult case. The patient was 52 year old female. Her main problem was low back pain and radiating pain to Rt.leg. The radiography evaluations show the degenerative scoliosis with degenerative spondylolisthesis L4 on L5. Pf. Wang performed decompression very carefully. However, we had experience of incidental dura injury. Dural tear was not an uncommon complication of spinal surgery. Pf. Wang was not embarrassed at this situation. He performed the dural repair and finished the operation successfully.



Degenerative scoliosis and degenerative spondylolisthesis on images

3rd June (Wed)

This day was the spine conference day. This day was my last day in Xi-jing hospital, too. I had presentation about my fellowship experience. I was grateful from the bottom of my heart for hospitality during my stay.

Cultures and Travel

Xi'an has many important historical sites. The bell-tower and drum tower are in the middle of the city. They provide the beautiful nightscape.



Bell tower and drum tower

Xian is surrounded by a well-preserved city wall which was reconstructed in the 14th century. If you visit this place, you may experience a trip to the past.



The city wall

The giant wild goose pagoda is well over 1,000 years old and have survived great earthquakes. You can see the largest fountain in the Asia. You can enjoy fountain show in the evening



Giant wild goose pagoda

The terracotta army is one of the world heritage sites in China. You can experience the wonder of ancient pottery technology



Terracotta army

Epilogue

This fellowship gave me the inspiration for spine surgery. It is my great honor to attend the operation with Pf. Luo and Pf. Wang. There are so many great surgeons in Xi-jing hospital. They provided great hospitality to me. I will never forget this sincerely hospitality.

I specially thank to the APSS committee and Pf. Mun-Keong Kwan for choosing me for clinical fellowship 2015. I also thank to Jenny Wong for great arrangement.

Logbook: Operations attended during this fellowship

Date	Day	Age	Sex	Diagnosis	Procedure	Surgeon	My role
May 19	Tue	51	M	HCD, 45,56	ACDF C456	Pf. Wang	Observer
		53	M	Ruptured disc L45	TLIF L45	Pf. Wang	Observer
		50	M	Spinal stenosis L45	TLIF L45	Pf. Wang	Assistant
May 21	Fri	68	F	Spinal stenosis L45	Decompression	Pf. Luo	Observer
		73	F	Spinal stenosis L45	TLIF L45	Pf. Luo	Observer
May 26	Tue	48	F	Lytic spondylolisthesis L45	TLIF L45	Pf. Wang	Observer
		43	M	Recurred disc L45	L & D	Pf. Wang	Observer
		33	F	Huge disc herniation L45	TLIF L45	Pf. Wang	Assistant
May 28	Fri	58	F	Spinal stenosis L45	TLIF L45	Pf. Wang	Observer
		50	M	HCD, C56	ACDF C56	Pf. Wang	Observer
June 2	Tue	52	F	Spinal stenosis L45S1	TLIF L45S1	Pf. Wang	Observer
		64	M	Spinal stenosis L45	TLIF L45	Pf. Wang	Assistant