

Report for APSS Deputy Synthes Spine Clinical Fellowship 2014

Fellow: Dr. **Kyung-Chung Kang**, M.D.

Assistant professor

KyungHee University Hospital, Seoul

Guide: Dr. **Zhuojing Luo**, M.D.

Professor,

Director of Department of Orthopedic Department

The 4th Military Medical University, Xian, China

Duration: 8 Dec. - 29 Dec. 2014

Centre's visited:

Xijing Hospital, Xian, China

I applied for the Asia Pacific Spine Society (APSS) - Deputy Synthes Spine Clinical Fellowship 2014. My application was accepted by the committee. It took place from 8th Dec. to 29th Dec. 2014.

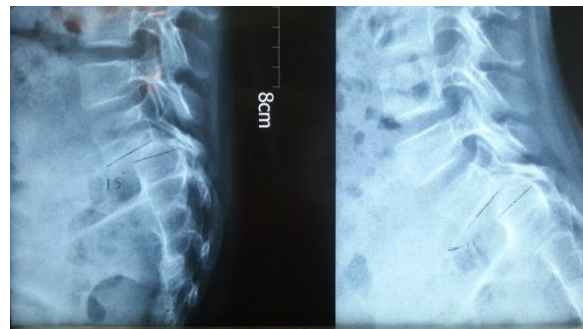
I landed in the vast continent in the world that has long history and glorious civilization at 8th Dec. I started my fellowship.

The scale of Xijing hospital was very large. There was a separate building for orthopedic department. First floor consisted of only laboratory part. Cell biology, biomechanics, regenerative medicine section and so on were studied in the lab. I was guided to spine section that was located in fifth floor. In that place, I met prof. Luo for the first time. Prof Luo

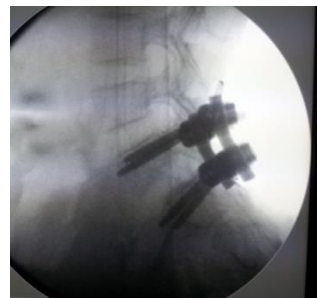
gave me the red-carpet treatment. He kindly introduced me the system and place of Xijing hospital. He was a director of orthopedic department in Xijing hospital. He joined all kinds of spine surgery and handled everything. He seemed to be very busy, but performed an act of kindness. I stayed a hotel around the hospital. Because weather is not colder than in our country, I could do my fellowship comfortably.

From the next day of my arrival, I joined the operation and clinics. I have seen a lot of operation and patients and introduced some memorable cases.

Case 1:



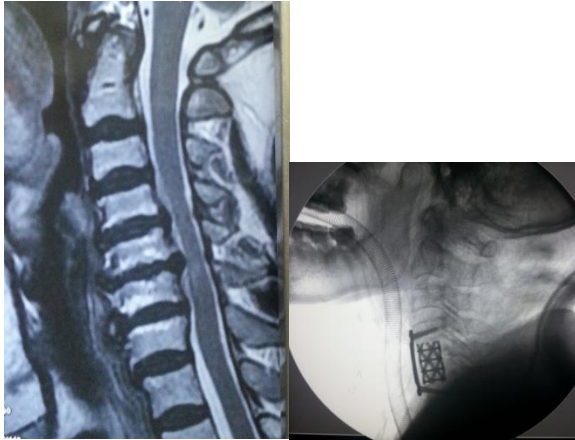
Developmental spondylolisthesis. This was the first case that I saw in Xian. The patient is a 8 year-old boy. He showed unstable L5-S1 spondylolisthesis with elongated isthmus. He showed round-shape upper end plate of S1 and focal kyphosis.



Posterior lumbar interbody fusion with allograft was successfully done. I have not seen before in our

country.

Case 2

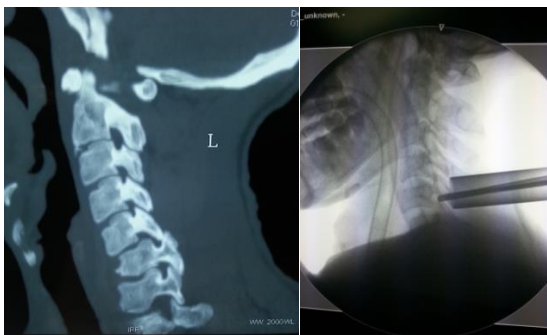

Severe myelopathy and C5 corpectomy was successfully done.



Prof. Luo used special corpectomy device and he performed corpectomy very easily. It took just one hour to perform corpectomy with this device.

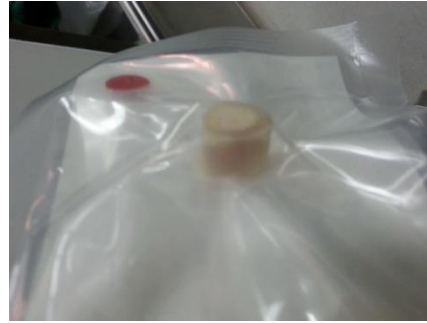Case 3



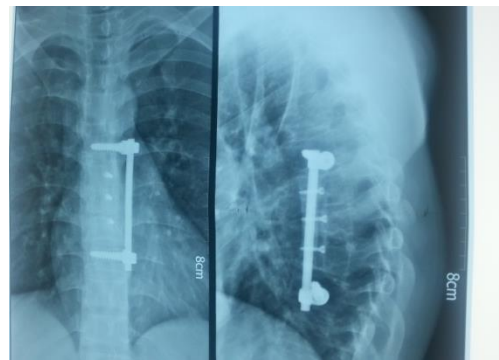
In China, minimal invasive surgery was popular. This patient showed C5-6 unilateral facet dislocation. The reduction was successfully performed by tube and

endoscopy very easily.

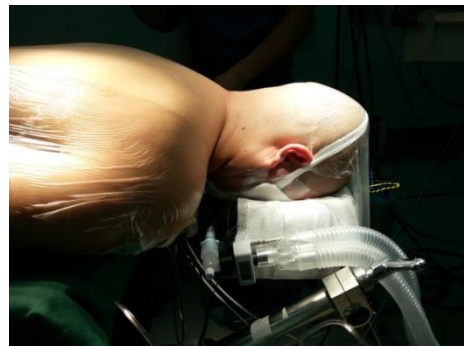And so on



Fresh-frozen allograft was usually used in interbody fusion. I think that this may be better than other synthetic materials.

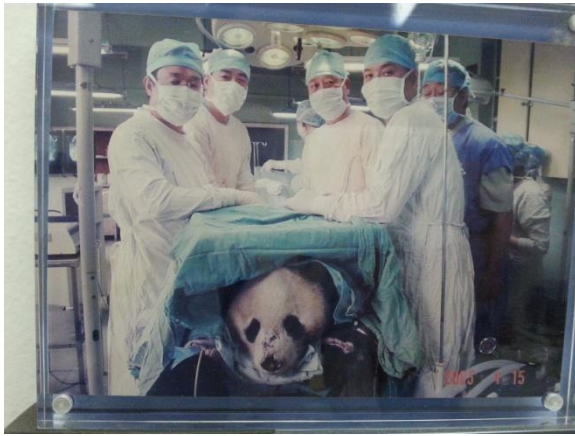

This patient came to out-patient clinic. ALIF was performed using fibular bone. Union seemed to be good. The fibular bones were united by using small screw. It see



A patient was positioned for posterior cervical surgery. All position was made by using soft band gently. They used double soft horse-shoe type

positioner for prevention of injury in face and used very soft elastic sticker for the position.



Prof. Luo showed a very interesting photo. He operated Panda' back for fracture. Panda is a national treasure in China. I could see Chinese people's affection for Panda.

Xian is famous for a lot of China's ancient treasures. During holidays, I visited a few interesting places around Xian.

I would like to introduce 3 places in Xian.

1) Tomb of Qin Shi Huang (Terra Cotta)

The Terra Cotta Warriors and Horses are the most significant archeological excavations of the 20th century. Work is ongoing at this site, which is around 1.5 kilometers east of Emperor Qin Shi Huang's Mausoleum in Lintong, Xian, Shaanxi Province. It is a sight not to be missed by any visitor to China.



2) Huashan mountain

Situated in Huayin City, Mt. Huashan is 120 kilometers (about 75 miles) from Xian. It is famous for natural vista of steep and narrow paths, precipitous crags and a high mountain range. Its five peaks are the representative attractions and each has its distinctive charms. It is one of the biggest mountain that I have seen.



3) Tea street (in traditional market)



The history of tea in China is long and complex. For The Chinese have enjoyed tea for millennia. Scholars hailed the brew as a cure for a variety of ailments; the nobility considered the consumption of good tea as a mark of their status, and the common people simply enjoyed its flavour. I can also feel great advantages of tea in Xian.



(Left) Prof Luo and me: He is a real soldier.

(Right) My new friend in Xijing hospital:

Dr. Hu, I, Dr. Wang and Jane

Prof Luo and his colleagues gave me the red-carpet treatment. I have seen many spine cases and learned a lot of things in Xijing Hospital. Additionally, I cannot forget special Chinese tradition and culture.

Thank you Prof Luo and my friend !.

Kyung Chung Kang from KOREA.